

**Review article:**

## **The Facial Translocation Approach for Management of Head and Neck Cancer**

**<sup>1</sup>Dr. Jaspreet Singh Badwal, <sup>2</sup>Dr. Upkardeep Singh, <sup>3</sup>Dr. Neha Bharti, <sup>4</sup>Dr. Shivani Garg, <sup>5</sup>Dr. Simarpreet Singh Batra**

<sup>1</sup>MDS, Oral and Maxillofacial Surgery, Ex.con. Civil Hospital Dhuri, District Sangrur, Punjab, currently self-employed.

<sup>2</sup>Department : General Surgery , Institute : Civil Hospital Dhuri, District Sangrur, Punjab.

<sup>3</sup>Department and Institute: Medical Officer at Civil Hospital Dhuri, District Sangrur, Punjab.

<sup>4</sup>MDS Oral and Maxillofacial Pathology , Department : Oral and Maxillofacial Pathology , Institute : Adesh Institute of Dental Sciences & Research, Bathinda, Punjab.

<sup>5</sup>PG student Oral and Maxillofacial Surgery , Department : Oral and Maxillofacial Surgery , Institute : Gian Sagar Dental College & Hospital, Rajpura, Punjab.

Corresponding author : Dr. Jaspreet Singh Badwal

---

**Abstract:**

The facial translocation approach is based on the principle of disassembling of vascularized midfacial composite units, permitting wide access for the treatment of extensive tumours affecting the skull base, both benign and malignant. In addition to surgical management of tumours at anterior skull base, the facial translocation approach can be employed in the treatment of tumours affecting the paranasal sinuses, nasopharynx, pterygomaxillary and infratemporal fossa, and the orbit.

**Keywords:** Facial translocation approach, skull base tumours, cancer skull base

---

**Background:**

The skull base is a complex anatomical region that separates the neurocranium from the facial viscerocranium. The various types of pathologies afflicting this region, may arise primarily within the skull base, or may extend there as secondary involvement by direct invasion from neighbouring structures. Apart from this, metastasis of distant origin may also invade this area.

Various surgical approaches have been developed to access different parts of skull base. Adequate exposure is the key to successful en-bloc and radical tumour resection in any region. In this regard, the transfacial swing osteotomies are highly valuable approaches to the skull base, facilitating a wide exposure to enable tumour resection, especially in the anterior and central areas of this region. The facial translocation approach (Fig. 1) is

based on the principle of disassembling of vascularized midfacial composite units, thus permitting wide access to the skull base and deep facial regions, followed by safe reconstruction after the midfacial units are reassembled.<sup>1</sup> The technique was popularized by Curioni,<sup>2</sup> Hernandez-Altemir<sup>3</sup> and Janecka,<sup>4</sup> who described in detail the techniques of unilateral and bilateral maxillo-cheek flap for access to the retromaxillary compartment. The facial translocation approach is based on three basic important principles<sup>5</sup> :-

1. The face is composed of specific facial subunits which have developed through embryonic fusion of nasofrontal, maxillary and mandibular processes.
2. Each of these subunits have specific neurovascular supply which is confined within the planes of fusion between

different subunits. Hence, when the subunits are divided along or near to these planes of fusion, there is minimum disruption of the neurovascular pedicle. This ensures the viability of the subunits, in response to displacement and reassembly.

3. Displacement of the facial units provides much greater tolerance to postoperative swelling, as compared to similar displacement of the contents of neurocranium.

**Classification:**

Janecka<sup>5</sup>(1995) classified the facial translocation approach, depending upon the structures displaced to gain access to skull base. This classification improves the ease of communication and comparison between the different technical variations of facial translocation approach. When required, the different types of this approach may be combined with a variety of craniotomies or craniectomies to facilitate radical block resection of tumours. The various technical variations of the approach are described below :

1. Mini Facial Translocation Central – this approach involves the lateral displacement of the ipsilateral nasal bone and nasal process of maxilla along with the attached medial canthal ligament, lacrimal duct and skin. The technique is employed for tumours affecting the medial orbital wall, ethmoid and sphenoid sinus, and inferior clivus.
2. Mini Facial Translocation Lateral – this technique involves the lateral displacement of malar eminence and zygomatic arch after the displacement of condyle and coronoid processes of mandible. Its principle application is for

access to tumours located in infratemporal fossa.

3. Standard Facial Translocation – The standard approach (Fig.2) involves lateral displacement of the ipsilateral maxilla, zygomatic bone and infraorbital rim, while maintaining the attachment to cheek flap. This is the classic technique developed first of all, and is the most widely used among the different types. Detailed description of this variation will be described later in the text.
4. Extended Facial Translocation Medial – this technique (Fig. 3) involves the standard facial translocation along with the nose and medial half of opposite side. It can be designed superior to the Le fort I level, so as to rotate the naso-ethmoido-maxillary skeleton, maintaining the alveolar process in its position, or including the ipsilateral alveolar process and palate in the displaced unit.
5. Extended Facial Translocation Medial and Inferior – this procedure incorporates the extended facial translocation medial in combination with ipsilateral mandibular split and lower cheek flap. It is employed for tumours extending below the plane of hard palate.
6. Extended Facial Translocation (Posterior) – the approach incorporates the displacement of the ear, temporal bone and posterior fossa, in addition to standard facial translocation.
7. Bilateral Facial Translocation – this technique joins the standard facial translocation of both sides, with or without a palatal split, the nose being incorporated in one of the sides. The procedure provides an extremely wide

exposure of both the infratemporal fossae, the central and paracentral skull base, full clivus, and both internal carotid arteries, permitting the resection of large lesions located in this area. A palatal split provides access to C2-C3, whereas adding a mandibular split offers clear access to C3-C4.

In all of the above types, an intracranial approach can be combined with transfacial access, when required.

**Surgical Technique:**<sup>2,3,4</sup>

The surgical technique will be described as pertaining to the standard hemifacial translocation. The patient is placed supine on the table, with the head positioned in a headrest. Oral-endotracheal intubation is done for airway management, though some cases require a preliminary tracheostomy or submental intubation.

A temporary tarsorrhaphy is carried out prior to placing the skin incision. The incision (Fig. 4) begins at the lateral canthus and continues through the inferior fornix of the lower eyelid, then through the medial canthus. The incision may be extended to the preauricular area laterally. At the medial end, the incision turns inferiorly, lateral to the nose, travelling along the side of the ala, towards the philtrum of upper lip, to end in a lip split. Thenceforth, a vertical incision is made intraorally in the vestibular sulcus. Subsequently, a paramedian palatal incision is made extending to the ipsilateral maxillary tuberosity. Preserving the attachments of the facial soft tissues to the underlying skeleton, the osseous structures subjacent to the incision are exposed, including part of the zygoma, the infraorbital rim and the nasomaxillary area, extending inferiorly to the alveolar process.

After the facial skeleton is exposed, the osteotomies are designed. The fixation plates are

placed at appropriate sites and bur holes are drilled for their placement at the end of the procedure. Following this, the bone cuts are made, so that the midfacial skeleton can be mobilized while pedicled to the hemifacial cheek flap. Different levels of osteotomies may be utilized – superiorly to Le Fort I level, or at the levels of hemi-Le Fort II or Le Fort III, including a midpalatal split. The anterior frontal branch of the facial nerve (1.5 - 2 cm. posterior to the lateral canthus) may be used as an anatomical reference plane of fulcrum, to rotate the maxilla with its overlying cheek flap, laterally and inferiorly. Next, the infraorbital nerve is electively sectioned along the floor of the orbit, the nerve being repaired at the end of the procedure. After the resection of the lesion, midfacial unit is replaced and the fixation plates are placed to fix the osseous structures in their previous position. The standard hemifacial translocation approach provides excellent access to the anterolateral regions of skull base, especially for lesions that extend from the nasopharynx to infratemporal fossa.

**Modifications of the approach to decrease morbidity and complications:**

Over the years, several modifications were introduced in the technique of facial translocation, to decrease the morbidity and complications associated with its use. A major complication reported after the procedure is necrosis and sequestration of the bone subunits.<sup>6,7</sup> This can be reduced if the osteotomised bone segment is left attached to the pedicle of cheek flap, ensuring minimal elevation of periosteum around the bone cuts. In addition, vascularised tissue cover<sup>8,9</sup> may be provided with temporalis muscle flap, lateral nasal flap or various free flaps. This also aids to prevent exposure of reconstruction plates.<sup>10</sup>

To preclude division of medial canthus and lacrimal system, the incision is turned just inferior to the position of medial canthus. Even in cases

where the medial canthus is sectioned, in order to prevent telecanthus, the ligament is tagged for easy identification. Placing the osteotomy at the level of lacrimal sac, prevents obstruction of nasolacrimal duct,<sup>11</sup> by the concept that the sac heals in a transected open fashion. Another problem is posed by transection of frontal branches of facial nerve. This can be prevented by limiting the incision to about 1 cm. posterior to the lateral canthus.

A common complication faced earlier was palatal fistula formation because of the use of a midpalatal incision. This is now avoided by either using the “palatal overlap flap” or the posteriorly based palatal flap of Raymond and Wei. In the palatal overlap flap technique,<sup>12</sup> described by Jackson IT (2008), the mucoperiosteum of the non-mobilized segment is incised anteroposteriorly, keeping the incision in a paramedian position, so as to provide a significant overlapping flap when closure is accomplished. The other technique of posteriorly based mucoperiosteal flap<sup>13</sup> was described by Ng Raymond and Wei W (2005) for elimination of palatal fistula after the maxillary swing procedure. The incision in the hard palate mucosa starts from the opposite lateral incisor (on the side of non-mobilized segment) and goes along the inner margin of upper alveolus on the side of maxilla that is to be swung, keeping 3 mm. intact mucosa from the inner border of gingiva. Posteriorly, the incision is extended on to the soft palate and then gently

curved behind maxillary tuberosity, on to the adjacent buccal mucosa. The hamulus of medial pterygoid plate lies posterior to this incision.

The most common complication reported in most of the series is nasal crusting and associated foul smell. In order to limit this, regular nasal irrigations must be done with warm saline, several times a day. CSF (cerebrospinal fluid) leakage is another problem associated with skull base surgery. It can be avoided by paying precise attention to meticulous reconstruction and closure of dead space, at the end of surgery.

#### **Discussion:**

Facial translocation approaches provide excellent access for the treatment of extensive tumours affecting the skull base, both benign and malignant. Any part of the orbit, maxilla or mandible can be mobilized, thus providing excellent exposure which facilitates three-dimensional tumour removal. A partial maxillary resection can be included, if required.

In addition to surgical management of tumours at anterior skull base, the facial translocation approach can be employed in the treatment of tumours affecting the paranasal sinuses, nasopharynx, pterygomaxillary and infratemporal fossa, and the orbit. The orbital swing can be performed to approach large orbital tumours lying inferior to the optic nerve and posterior to the globe.

Fig. 1 : Unilateral facial translocation as described by Hernandez-Altemir




Fig. 2 : A schematic diagram illustrating osteotomy line of standard facial translocation.

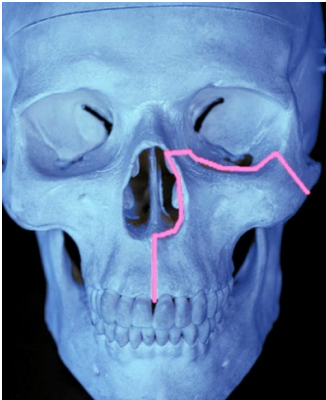


Fig. 3 : A schematic diagram illustrating osteotomy line of extended medial facial translocation.

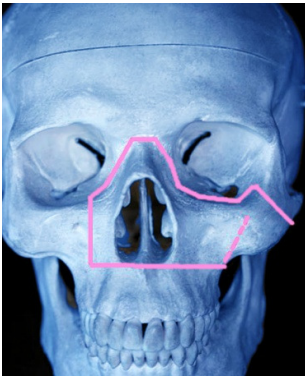
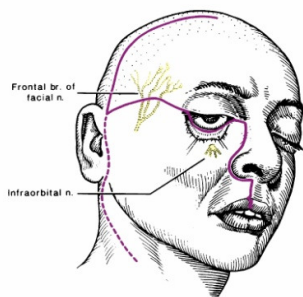


Fig. 4 : A schematic diagram illustrating the skin incision for facial translocation.



#### Conflict of interests

The authors declare that there is no conflict of interests that could influence this work.

#### Funding Acknowledgements

The authors declare that there was no financial aid obtained from any source for the preparation of this manuscript.

#### References:

1. Hao SP, Pan WL, Chang CN, Hsu YS. The use of the facial translocation technique in the management of tumours of the paranasal sinuses and skull base. *Otolaryngol Head Neck Surg.* 2003; 128: 571-575.

2. Clauser L, Vinci R, Curioni C. Dismantling and re-assembling of the facial skeleton in tumour surgery of the craniomaxillofacial area. History, surgical anatomy, and notes of surgical technique: Part I. *J Craniofac Surg.* 2000; 11: 318-325.
3. Hernandez- Altemir F. Transfacial access to the retromaxillary area. *J Maxillofac Surg.* 1986; 14: 165-70.
4. Janecka IP, Sen CN, Sekhar LN, Arriaga M. Facial translocation: a new approach to the cranial base. *Otolaryngol Head Neck Surg.* 1990; 103(3): 413-19.
5. Janecka IP. Classification of facial translocation approach to the skull base. *Otolaryngol Head Neck Surg.* 1995; 112: 579-585.
6. Wei WI, Ng RW. Complications of resection of malignant tumours of the skull base: outcome and solution. *Eur Arch Otorhinolaryngol.* 2007; 264(7): 733-39.
7. Hao SP. Facial translocation approach to the skull base: the viability of translocated facial bone graft. *Otolaryngol Head Neck Surg.* 2001; 124(3): 292-96.
8. Eldaly A, Magdy EA, Nour YA, Gaafar AH. Temporalis myofascial flap for primary cranial base reconstruction after tumour resection. *Skull Base.* 2008; 18(4): 253-63.
9. Pusic AL, Chen CM, Patel S, Cordeiro PG, Shah JP. Microvascular reconstruction of the skull base: a clinical approach to surgical defect classification and flap selection. *Skull Base.* 2007; 17(1): 5-15.
10. Sharan R, Iyer S, Chatni SS, Samuel J, Sundaram KR, Cohen RF, Pavithran K, Kuriakose MA. Increased plate and osteosynthesis related complications associated with postoperative concurrent chemoradiotherapy in oral cancer. *Head Neck.* 2008; 30(11): 1422-30.
11. Suarez C, Llorente JL, Munoz C, Garcia LA, Rodrigo JP. Facial translocation approach in the management of central skull base and infratemporal tumours. *Laryngoscope.* 2004; 114(6): 1047-51.
12. Jackson IT, Pieper DR. The palatal overlap flap: a modification of the maxillary swing procedure to prevent ascending infection. *Skull Base.* 2008; 18: 363-70.
13. Ng RWM, Wei WI. Elimination of palatal fistula after the maxillary swing procedure. *Head Neck.* 2005; 27: 608-612.